

INCIDENTAL ECHOCARDIOGRAPHIC FINDING OF COR TRIARIATUM SINISTER in 43years old MAN TRIATHLETE

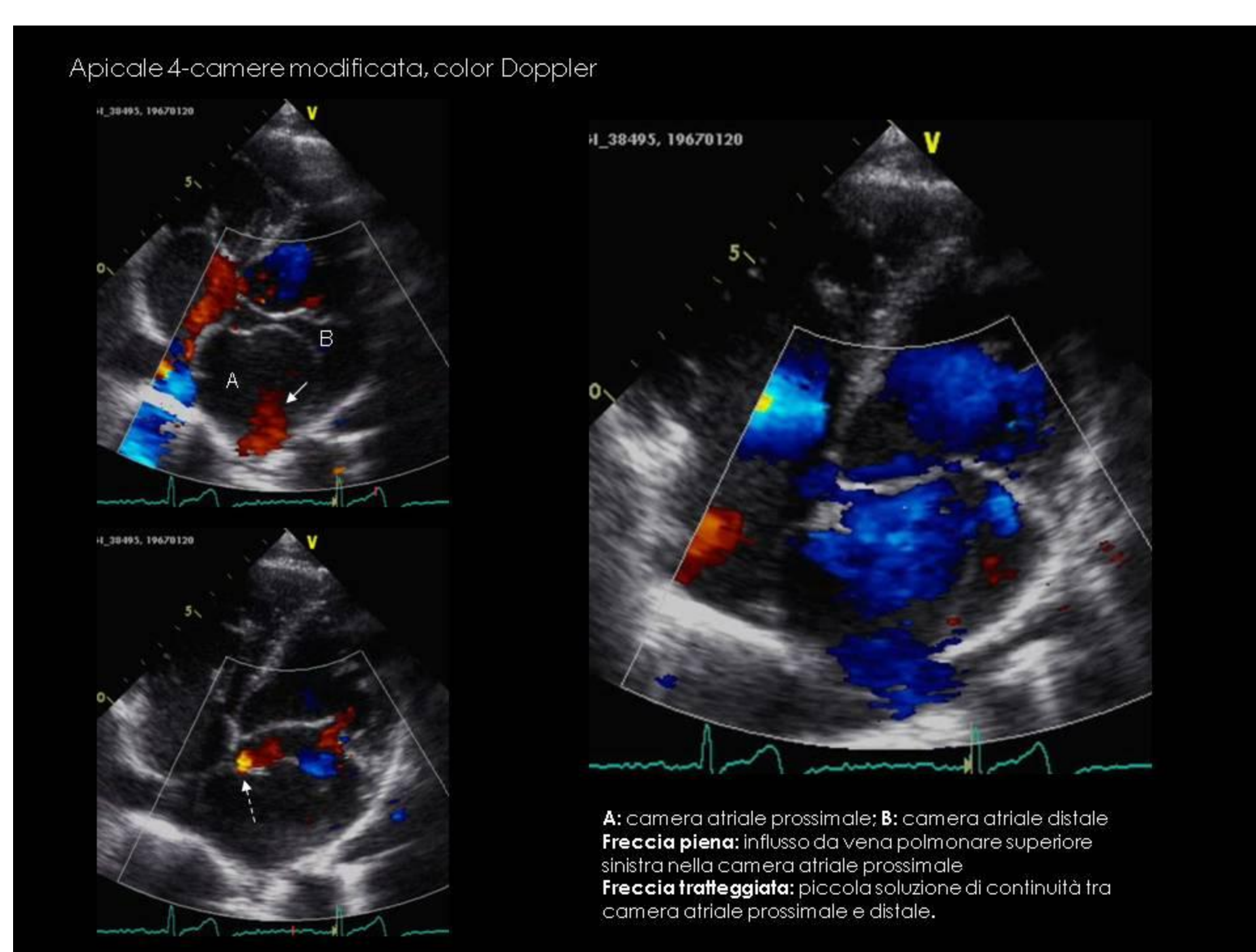
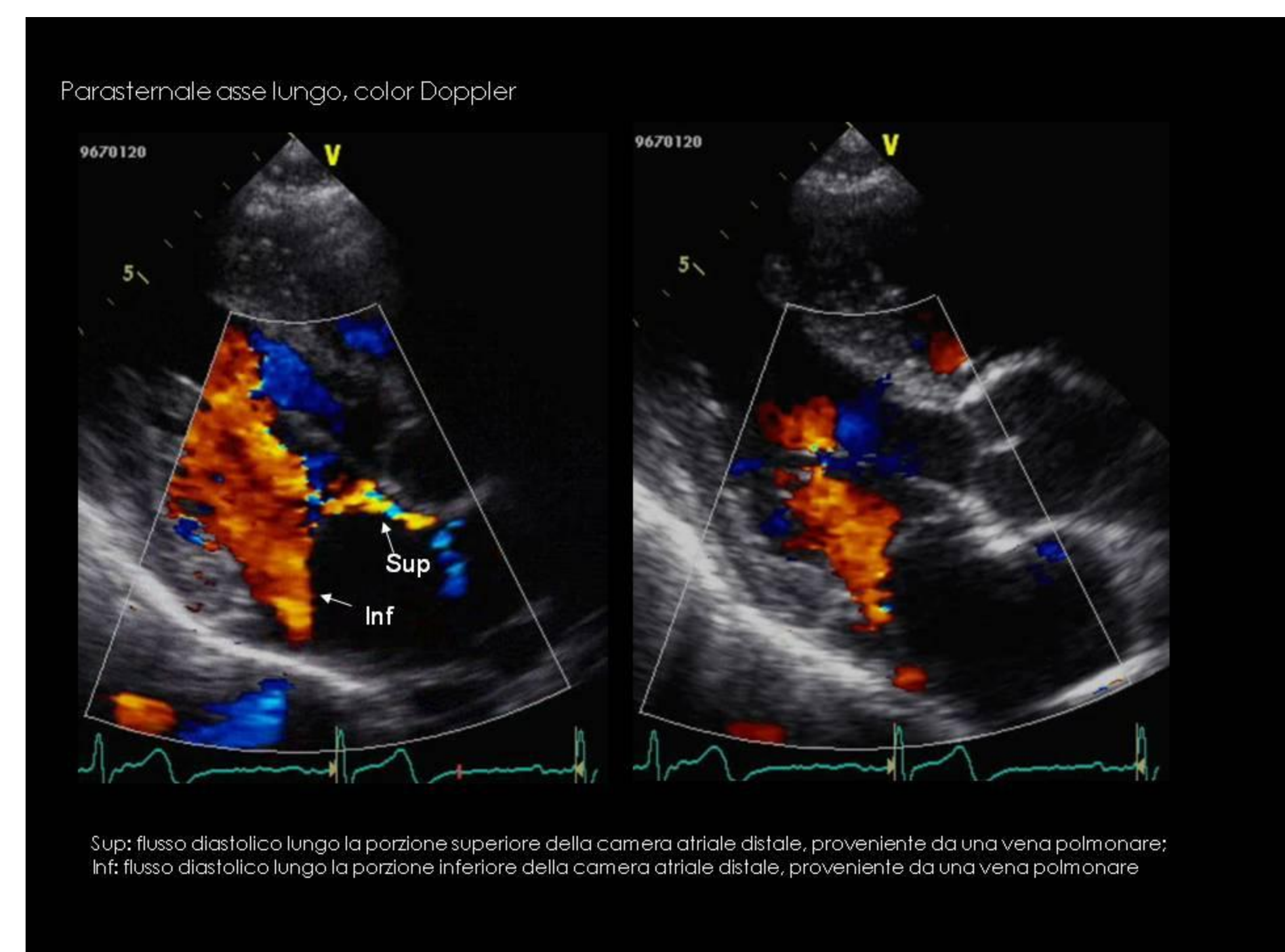
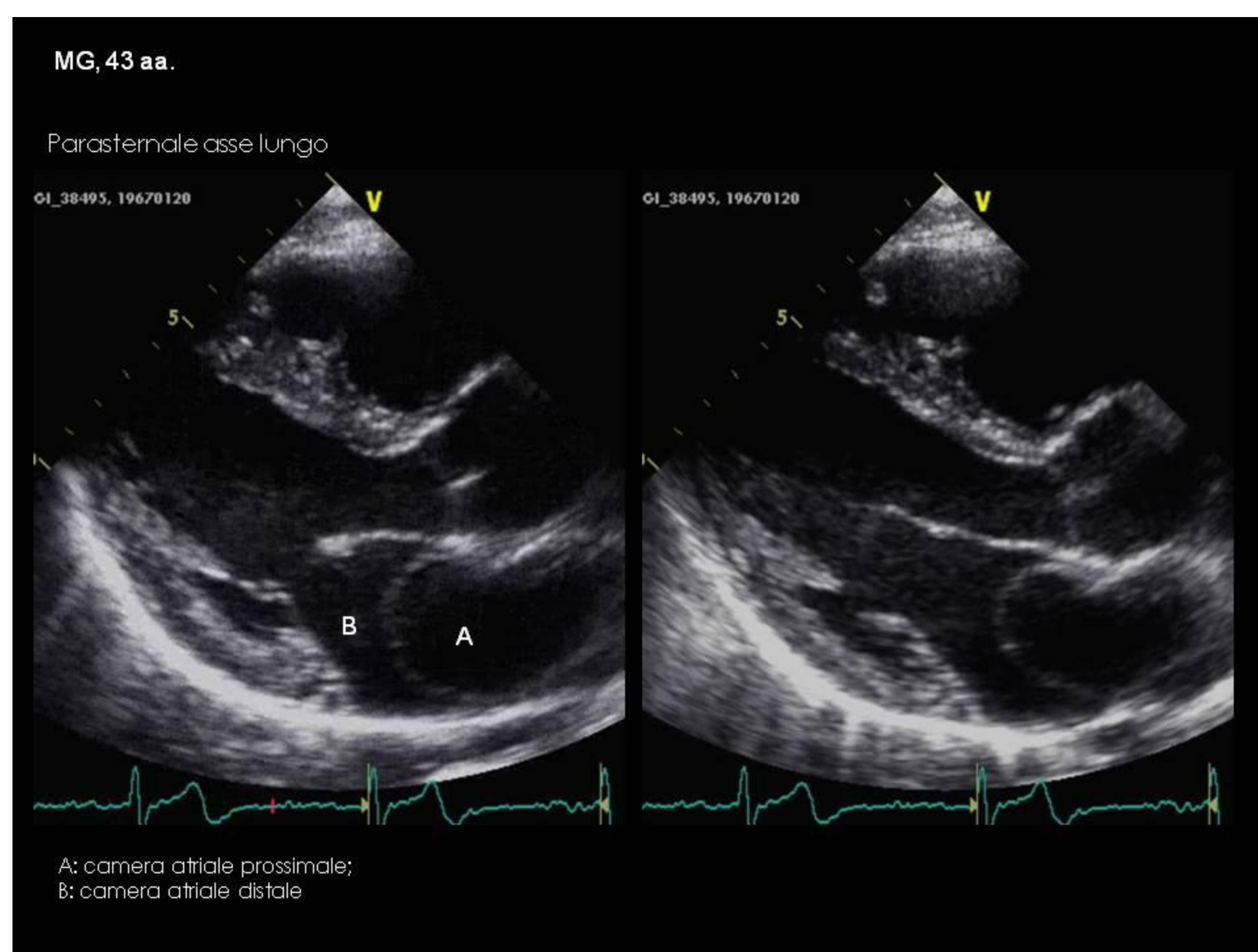
Massimo Bolognesi, M.D. *, Paolo Barbier, M.D. **

* Medicina dello Sport, 47522 Cesena (Italy)

** Centro Cardiologico Monzino (Italy)

ABSTRACT

A 43 healthy old man Age-Group Triathlete was referred to our sports medical center for screening preparticipation and abilitation in the triathlon competition. This athlete has been active in race triathlon and long distance cycling competition for the last 10 years, His family history revealed no known congenital or other cardiovascular disease and no known causes of premature sudden cardiac death in close relatives. He had no relevant past medical history and physical examination was unremarkable. Peripheral blood pressure was 110/70 mmHg. Resting 12-lead Electrocardiogram showed a sinus bradycardia and incomplete right bundle block (see figure). The cycloergometer and treadmill maximal exercise test showed a good performance, absence of any electrocardiographic abnormality, with peak cycling workload of 330 Watt, 15 Mets on Treadmill Astrand Protocol, and maximal heart rate of 165-170 bpm. Transthoracic echocardiogram demonstrated a left atrium divided into two compartments by a incomplete membrane appearing an incomplete thin diaphragm in all echographic windows (see figures and movies). Mitral valve appeared slightly dysplastic with mild regurgitation. Pulmonary artery pressure was estimated to be 25 mmHg. Hence the filling pressure were not elevated and the athlete was asymptomatic. Suspected diagnosis of Cor Triatriatum Sinister was performed. Subsequent echo 2D performed by expert echocardiographer and Cardiac RMI confirmed the diagnosis of Non obstructive Cor Triatriatum Sinister. The literature review has suggested that cor triatriatum has been incidentally diagnosed in asymptomatic adults, however in addition, this case provides new anatomical information on this congenital heart disease, and then explains the coexistence of excellent physical performance in the presence of a congenital heart defect.



OPEN QUESTIONS

- 1) echocardiography should be considered a second level examination or routinely performed in screening sport pre-participation ?
- 2) which further assessment must be conducted in this athlete ?
- 3) Guch (adult born with congenital heart disease) with no apparent signs of functional impairment should be a contraindication for competitive sports eligibility ?

CONCLUSIONS

Cor triatriatum is a congenital heart defect where the left atrium or right atrium is subdivided by a thin membrane, resulting in three atrial chambers (hence the name). Cor triatriatum is hence characterized by a fibromuscular membrane that divides the left atrium into two distinct chambers. In almost all cases, it is diagnosed in childhood, whereas adult cases are extremely rare.

The membrane may be complete or may contain one or more fenestrations of varying size. It can be treated surgically by removing the membrane dividing the atrium. In the **pediatric population**, this anomaly may be associated with major congenital cardiac lesions such as tetralogy of Fallot, double outlet right ventricle, coarctation of the aorta, partial anomalous pulmonary venous connection, persistent left superior vena cava with unroofed coronary sinus, ventricular septal defect, atrioventricular septal (endocardial cushion) defect, and common atrioventricular canal. Rarely, asplenia or polysplenia has been reported in these patients. In the adult, cor triatriatum is frequently an isolated finding. In the **adult**, cor triatriatum sinister can be as follows:

- o Asymptomatic (found incidentally on cardiac imaging)
- o An isolated finding with a large non-restrictive communication between the superior and inferior left atrial chambers
- o Associated with minor congenital defects such as patent foramen ovale, atrial septal defect, or persistent left superior vena cava